

DICEPHALIC MONSTER

A Case Report

M. L. GOENKA

A monster is a foetus with developmental abnormality of sufficient degree to interfere with its life or normal growth. Human foetal monsters are rare and has been reported in Indian literature from time to time. The number of monsters which go on to full term is about 0.6 per cent. The incidence of conjoined twine varies from 1 : 50,000 births (Feldman, 1937) to 12,83,000 deliveries (Mortimer and Kristbaum, 1962). Conjoined twine are monovular and can vary in degree of union and extent of sharing of vital organs. Most commonest variety is of thoracopagi or sternopagi. In these cases the lower parts of each foetus are fused into one forming a single trunk, surmounted by two heads of equal size. The following case, which was delivered vaginally, is worth reporting for its rarity.

second was lying in left iliac fossa. Her prenatal course was uncomplicated.




Fig. 1

CASE REPORT :

Mrs. B., 29 years old, Hindu Assamese female, second gravida was admitted on 15-10-85 with history of labour pain. She was carrying a 38 weeks pregnancy. Her expected date of delivery was on 29-10-85. She visited antenatal clinic thrice in the current pregnancy. Her first check up was at 8 weeks time and no abnormality was detected. Second check up was done at 28 weeks time and multiple pregnancy was suspected. At 34 weeks on 16-9-85 X-ray was taken (fig. 1) and twin pregnancy was diagnosed with one foetus presenting as vertex and head of

Past obstetric history revealed a full term normal delivery 2 years back. The female child is alive and well. Family history is not suggestive of any twin pregnancy. She was of average built and height. On admission the pulse rate was 90 per minute and temperature 98° F. There was no pallor or oedema. B.P. was 120/90 mm of Hg.

Abdominally the uterus was of 36 weeks' size. Head was fixed and poles were palpable. Uterine contractions were strong and frequent. Only one foetal heart sound was located which was regular. On vaginal examination :

os was 4 cm. dilated, effacement-50 per cent and station of head at -3 position. Membranes were present. The pelvis was adequate.

Her haemoglobin was 12 Gm per cent. Her blood group was 'A' Rh positive. Labour was allowed to continue. At 4.00 a.m. the cervix was fully dilated and the patient started bearing down. Foetal heart sounds were 144 per minute and distinctly audible. Despite good uterine contractions the descent of the head was unusually slow. As there was no further progress for almost one and half hours, a low forceps delivery of first baby was planned under pudendal block & RML episiotomy.

With great difficulty face was delivered, which was cyanosed. Attempt to deliver the anterior shoulder failed. It was thought that the twin may have locked. Head of first baby was pushed anteriorly and left hand was

introduced inside vagina to dis-engage or push the other head up. In this attempt we could not push the head but could bring down one hand. Head and the hand were pulled down with much difficulty and we could bring out the anterior shoulder. (During this manoeuvre humerus was fractured). Following the delivery of anterior shoulder, other head and two palms fused together with ten digits were delivered with little pull. This gave us the clue about the presence of a monster. After the delivery of the second head, the rest of the foetus was delivered with ease. Within 5 minutes normal single placenta, weighing 560 gms. with one umbilical cord, was delivered without any difficulty. Uterine cavity explored to rule out rupture and other anomalies. Episiotomy was sutured after ruling out injury to cervix.

On examination the foetus (Fig. 2 & 3), it was found to be a fresh still born



Fig. 2

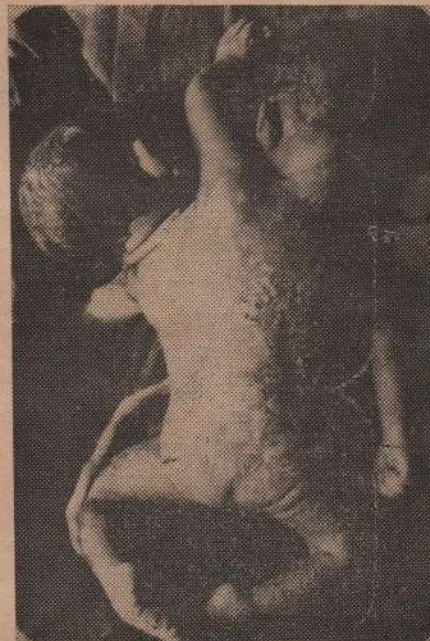

Fig. 3

female dicephalus double monster weighing 3400 gms. The union was on lateral aspects of body upto shoulders. Above the shoulders there was one hand (slightly larger than other two hands) having ten digits. There were two heads of equal size. Chest had only two nipples. The crown heel measurement from both heads was 39 cm. The umbilical cord measured 45 cm. in length and was eccentrically inserted in the placenta. The cord contained two arteries and one vein. The placenta was 20 cm in diameter.

Post mortem examination of the twin was not done as the specimen was kept for our museum. X-ray of the specimen (Fig. 4) showed double spine formation. The puerperal course was uneventful.

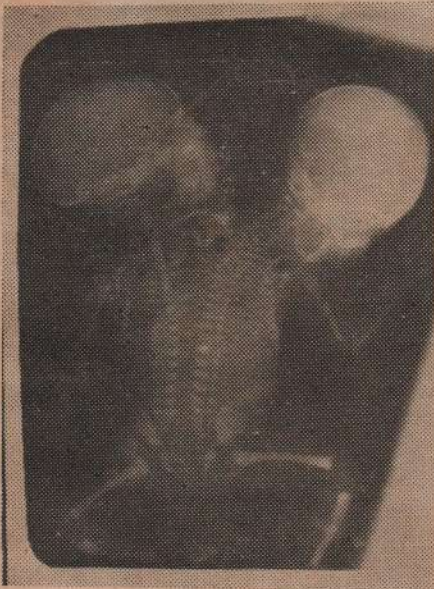

Fig. 4

The lactation was suppressed with two intramuscular injections of mixogen.

DISCUSSION :

Usually these malformations are not diagnosed until labour is well advanced

in second stage and there is usually unexplained arrest of a partly delivered foetus. If diagnosed early, it is less hazardous to deliver the baby by caesarean section than to try difficult intra-uterine manipulation.

Following points are usually considered in a antenatal radiological diagnosis.

1. The babies face each other (if union is on anterior surfaces).
2. Both foetal heads remain at the same level.
3. Thoracic cages of the foetuses remain together with crowding of ribs.
4. Separate distinct fat lines are not visualised.
5. Unusual backward deflection of the cervical spines.
6. Another X-ray at a later date will show that there is no change in relative position of the foetuses.

In the present case the antenatal radiological diagnosis was missed. More antenatal diagnosis will be made if occurrence of this rare condition is suspected in twin pregnancies.

REFERENCES :

1. Chopra, J., Sathyabhama, V., Indira, C. and Seetha, T: Conjoined Twins. *J. Obst. & Gynae. India.* 32 : 136, 1982.
2. Pal, S. K. and Choudhury, S. K. : Thoracopagus tetrabrachius tetrapus. *J. Obst. & Gynae. India.* 27 : 454, 1977.
3. Saraogi, R. M. and Vaidya, P. R. : Undiagnosed dicephalic monster. *J. Obst. & Gynae. India.* 31 : 158, 1981.
4. Sinha, R. : Conjoined twins associated with accidental haemorrhage and rupture of the uterus. *J. Obst. & Gynae. India.* 30 : 830, 1980.